


Combined Value Calculations

Once the medical history, medical exam and percent impairments of the injured worker are determined for all the allowed conditions, the number crunching begins to calculate the total whole person impairment. Loss of function is expressed as a percentage impairment of the whole body based on the *Guides to the Evaluation of Permanent Impairment, 5th edition*. Multiple impairments are **combined** - not added - to yield a final total whole person permanent impairment.

The formula: $\% \text{ impairment} = [A + B(1 - A)] \times 100$ is the basis of this calculation, where A and B represent the decimal impairments to be combined. Using this formula, one can combine as many impairments as needed, without exceeding 100%.

For example, if an injured worker has the allowed condition of bilateral knee DJD, which resulted in bilateral total knee arthroplasties, both with a poor result, each knee would have a permanent impairment of 30% whole person. The combined impairment of both knees totals 51% whole person - (not 60%). The Combined Values Chart (Pages 604 - 606) tabulates the result of these combinations if a calculator is not available.

With any measurement and calculation, units must be specified. Some tables in the *Guides* give impairment with respect to the upper extremity, hand or digit. In these cases, the impairment needs to be converted to whole person. Consider the impairment of an index finger DIP joint fused in 50° flexion. See the box below to show the conversion to whole person impairment.



Finally, suppose this injured worker also has an allowed cervical radiculopathy, DRE Cervical Category III, 15% whole person impairment. What is the combined impairment of the DIP joint and the cervical radiculopathy? If you answered 18% whole person, you have a good understanding of combining impairment values.

R. Stanko MD, MS

CONVERSION TO WHOLE PERSON IMPAIRMENT EXAMPLE

	Percent of Index Finger Impairment	Value of Hand Imp. Per Index Finger Imp.	Value of Upper Extremity Imp. Per Hand Imp.	Value of Whole Person Imp. Per Upper Ext. Imp.	Percentage of Whole Person Impairment
Conversion Factor	39% X →	0.20 X → Hand Impairment	0.90 X → Upper Extremity Imp.	0.60 X → Whole Person Imp.	= 4% (rounded to nearest integer)
Guides Reference	Figure 16-21, pg. 461	Table 16-1, pg. 438	Table 16-2, pg. 439	Table 16-3, pg. 439	

Best Wishes

to Dr. Terrence Welsh

Dr. Welsh has served as Chief Medical Advisor at the Industrial Commission since July 2007. He will join a physician group in Northern Kentucky. Dr. Welsh will be missed and we wish him good luck in his future practice and endeavors.

Meet the Interim Chief Medical Advisor, Robin G. Stanko MD, MS

Dr. Robin Stanko became interim Chief Medical Advisor in February 2015. A native of Westlake, Ohio, Dr. Stanko is a graduate of Northwestern University and received his MD and MS degrees from The Ohio State University College of Medicine. Dr. Stanko has worked in private practice in Dayton and Westerville for 32 years.

He is certified by the American Board of Physical Medicine & Rehabilitation and the American Board of Electrodiagnostic Medicine. Dr. Stanko has done independent medical exams for the Industrial Commission

for over twenty years and serves on the BWC Health Care Quality Assurance Advisory Subcommittee. He is a Fellow of the American Association of Disability Examining Physicians. He also teaches chemistry at Clark State Community College in Springfield, Ohio.

In this position, Dr. Stanko is responsible for the development, implementation and administration of IME exams, physician recruitment and training. Dr. Stanko can be reached at (614) 466-1266 or contacted through email at robin.stanko@ic.ohio.gov.

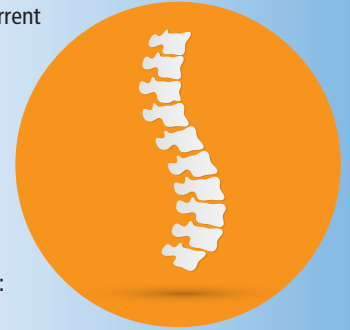DRE vs. ROM Spine Evaluation Methods

Chapter 15 of the *Guides to the Evaluation of Permanent Impairment, 5th Ed.*, describes the principles of assessment for the spine (vertebral bodies, and associated muscles, ligaments, disks and neural elements). To determine impairments of the spine, the *Guides* provides two methods of evaluation: the Diagnosis Related Estimate (DRE) Method and the Range of Motion (ROM) Method. The *Guides* specify the DRE method is the primary method to determine spine impairment in an injured worker who has had a distinct injury. Please note, **the examiner cannot simultaneously apply both methods to the same spine region.** When an injured worker has claim allowances for more than one spinal region, the DRE method or the ROM method can be applied to a particular region as appropriate. The spine impairment percentages from the different spine regions are then **combined.**

There are multiple DRE Categories for each of the three spinal regions. For instance, a DRE Lumbar Category I defines a lumbar spine injury with no significant clinical findings and represents 0% whole person impairment. DRE Lumbar Category III defines radiculopathy, and indicates a 10%-13% whole person impairment. A one-level fusion is described by DRE IV, with a 20%-23% WPI (Table 15-3, p.384). Within this range, the examiner can assign a higher percentage if residual symptoms or objective findings impact the ability to perform Activities of Daily Living (p. 381).

When a condition cannot be classified in a DRE Category, the ROM method may be used in certain situations:

- Impairment of the spine caused by illness
- Multi-level involvement in the same spinal region
- Two or more fusions in the same spinal region
- Recurrent radiculopathy from recurrent HNP in the same spinal region
- Multiple episodes of other pathology producing alteration of motion segment integrity and/or radiculopathy



The ROM Method consists of combining impairments from four areas: diagnosis (p.404), range of motion, motor and sensory impairments. (However, range of motion impairments **within a spinal region** are added together).

An injured worker may have multiple, similar allowed conditions within a spinal region distributed over various BWC claims. The challenge is to determine the overall whole person impairment of all the allowed conditions related to the spinal region which can be accomplished by selecting the DRE Category that describes the most severe impairment documented by medical history and physical exam.

R. Stanko MD, MS

Did You Know?

The word "resolved" has different meanings with respect to medical and legal issues in an IC PTD exam. Referring to an allowed condition as "resolved", in the legal sense, implies the allowed condition no longer exists. Physicians use "resolved" to indicate that a physiologic or anatomic repair process has returned to baseline. For example, the ecchymosis of a knee contusion may fade, but the allowed condition remains in the claim. Physicians must accept and evaluate all allowed conditions when doing a PTD exam and opining on permanent impairment. Consequently, avoid the use of "resolved" when referring to an allowed condition. Instead, simply state the allowed condition has a zero percent whole person permanent impairment based on the physical exam findings at the time of the permanent Total Disability examination.

MediScene's Continuing Medical Education

All providers doing musculoskeletal physical exams or psychological exams for an Industrial Commission PTD exam



will undergo a reappointment process every five years. As part of this process, providers need to document 8 hours of continuing medical evaluation pertaining to specialty impairment evaluation. To assist in this endeavor, *MediScene* will provide IME case presentations that can earn you 1 hour (Category II) of CME credit toward your IC education requirement. The following pages contain a case presentation for you to complete. Analyze the case, provide a discussion, impairment rating, opinion and physical strength rating and submit it to the IC Medical Services department. Submissions can be emailed to wanda.mullins@ic.ohio.gov, sara.castle@ic.ohio.gov or faxed to 614-466-1051. An answer sheet will be provided after submission of your CME.

CASE PRESENTATION

Ohio Industrial Commission - Specialist Report

CLAIMANT

Paul Beagle

ALLOWED CONDITIONS

SPRAIN RIGHT SHOULDER; ROTATOR CUFF TEAR-RIGHT; RIGHT A/C JOINT INJURY WITH CARTILAGE TEAR; BURSITIS RIGHT SHOULDER; IMPINGEMENT SYNDROME RIGHT SHOULDER; ADHESIVE CAPSULITIS RIGHT SHOULDER, SPRAIN OF NECK; CERVICAL HERNIATION AT C6-7.

HISTORY

In 1994, he was forcefully wrenching a nozzle off a press, pulling and stretching his neck, right shoulder and arm. Mr. Beagle reports no recent therapy for his allowed conditions. He states his neck is painful which is "pretty much constant". Mr. Beagle states he gets pain in the right shoulder if he tries to lift a coffee cup. Consequently, he states he tries to do most of his activity with his left arm. He states no further surgery is planned for the right shoulder. Mr. Beagle states he can drive short distances to the grocery store.

Medical records indicate Dr. Weimaraner performed the following surgeries: Right distal clavicle resection (4/24/95); Right shoulder open decompression, inferior acromioplasty, excision of coracoacromial ligament, bursectomy, modified Mumford, rotator cuff repair (4/01/09); Arthroscopy of the right shoulder with removal of multiple adhesions (5/23/10). An MRI of the cervical spine (6/11/11) noted minimal cervical spondylosis with minimal osteophyte disc effacement of the thecal sac at C56 and C67. An MRI of the right shoulder, (2/16/13), showed extensive post-surgical changes, a small tear of the distal supraspinatus tendon, post acromioplasty changes and degenerative changes within the superior labrum, and cystic changes within the superior posterior lateral humeral head. EMG testing in March 2014 reported no acute cervical radiculopathy.

MEDICAL HISTORY REVIEW

Medications: Rarely takes Tylenol #3 (twice in last week), Prilosec

Past Medical History: +hypertension

Review of systems: Reports occasional epigastric pain

Social History: Smokes ¼ PPD, last worked 3/1/95

Family History: +Diabetes, father

Surgery: Multiple shoulder surgeries

Allergies/Reactions: NSAIDs.

PHYSICAL EXAM

The IW is alert and in no acute distress. There is 5/5 strength for all muscle groups in the left upper extremity. There is 5/5 strength noted for right finger abduction, wrist extension, elbow flexion and extension; and 5-/5 strength or right shoulder abduction, external rotation and internal rotation limited by pain. DTR testing shows 1+ reflexes for the bicep, brachioradialis and triceps bilaterally. Sensation to light touch is decreased over the scars and over the proximal right deltoid, but otherwise intact in the upper extremities bilaterally. Mid-arm circumference measures 37 cm right; and 38 cm left. A cervical compression test is negative. Neck range of motion shows 30° flexion, 20° extension, 20° right lateral flexion, 20° left lateral flexion, 40° right rotation and 0° left rotation. There is moderate tenderness noted with palpation of the right cervical paraspinals and trapezius.

There is tenderness with palpation of the right anterior shoulder, acromioclavicular joint and glenohumeral joint space. There is a 6 cm, 10 cm over the right shoulder. There is tenderness with palpation of the right proximal bicipital tendon. Right shoulder range of motion shows 95° forward flexion, 40° extension, 90° abduction, 5° adduction, 35° external rotation and 15° internal rotation. Radial pulses are intact bilaterally, 80 per minute and regular. The skin shows normal color and temperature in the upper extremities bilaterally. Extremity temperature is 34 °C bilaterally. He is right handed.

DISCUSSION

SPRAIN RIGHT SHOULDER; ROTATOR CUFF TEAR - RIGHT; RIGHT A/C JOINT INJURY WITH CARTILAGE TEAR; BURSITIS RIGHT SHOULDER; IMPINGEMENT SYNDROME RIGHT SHOULDER; ADHESIVE CAPSULITIS RIGHT SHOULDER.

How do you assess right shoulder impairment?

What Tables / Figures in the *Guides, 5th Edition* do you use to calculate impairment?

Does his shoulder surgery affect the impairment?

SPRAIN OF NECK; CERVICAL HERNIATION AT C5-6.

What method do you use to calculate cervical spine impairment?

What Tables / Figures in the *Guides, 5th Edition* do you use to calculate impairment?

How do calculate impairment for neck and shoulder conditions?

PHYSICAL STRENGTH RATING:

What impairments on physical exam affect strength?

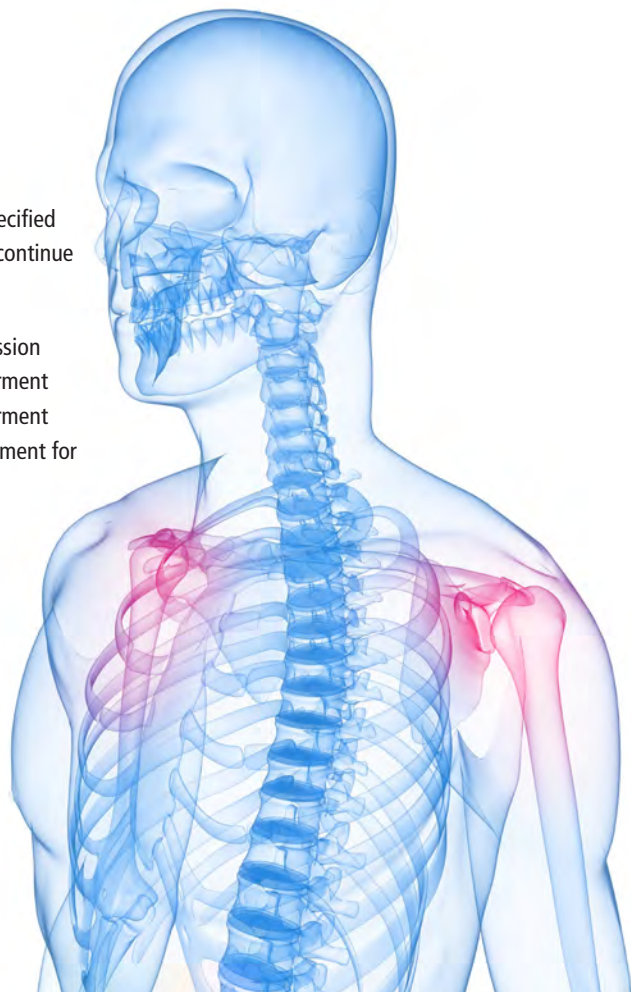
What impairments on physical exam affect ADL activities?

With respect to allowed conditions, what is your PSR? Why?

PROVIDE OPINIONS ON THE FOLLOWING ISSUES:

1. Has the Injured Worker reached maximum medical improvement with regard to each specified allowed condition? Briefly describe the rationale for your opinion. If "yes," then please continue to items #2 and #3.
2. Based on the *AMA Guides, 5th Edition*, and with reference to the Ohio Industrial Commission Medical Examination Manual, provide the estimated percentage of whole person impairment arising from each allowed condition. Please list each condition and whole person impairment separately, and then provide a combined whole person impairment. If there is no impairment for an allowed condition, indicate zero (0) percent.
3. Complete the enclosed Physical Strength Rating. In your narrative report, provide a discussion setting forth physical limitations resulting from the allowed condition(s).

Case presentation submissions should be emailed to wanda.mullins@ic.ohio.gov, sara.castle@ic.ohio.gov or faxed to 614-466-1051.





Keeping You Up-to-Date with the Industrial Commission's Medical Services • September 2015

Uploading Exam Reports to ICON

Permanent Total Disability IME reports can now be directly uploaded from your computer to the Industrial Commission of Ohio Network (ICON). For specialist exams completed within the last 60 days, follow these steps to upload a report:

1. Log into ICON, click **Report Upload**.
2. From the Upload Report Page, click **Browse**, locate the file to be uploaded (the report must be in PDF or DOCX format).
3. At Upload Report for Claim, **select the Claim #** of the IW examined from the drop down menu.
4. Click the **Upload** button.
5. Upon successful upload completion, ICON will acknowledge an **Upload Report Confirmation**.

Reminders:

- Your report **must have a digitized signature**; an electronic signature cannot be accepted
- The File Name must be less than 25 characters
- The transferred file size must be under 10MB
- For more information please refer to the *July 2015 ICON Provider Guide*

Ohio Industrial Commission
Timely, impartial resolution of workers' compensation appeals

NEWS & INFO | I.C.O.N. | CONTACT | FORMS | IC POLICIES

Industrial Commission Online Network **IC Provider Home Page**

Guide to I.C.O.N.
IC Provider Home
Provider Profile
Report Upload **1** **Find a Claim**
Security
Log out

Find a claim by entering the claim number **OR** the injured worker's Social Security last name into the appropriate search boxes below.

Claim Number **OR** SSN

Industrial Commission Online Network **IC Provider Upload Report**

Upload Report

Select Report to Upload: C:\Users\egaray\Desktop\JDoeMedRpt_061815.pdf **Browse...** **2**
Preferred Format: PDF. Will also accept: DOC, DOCX.

Upload Report for Claim: 98-765432 - John Doe **3**

UPLOAD **4**

Industrial Commission Online Network **IC Provider Upload Report**

Upload Report Confirmation

You have sent file "VivesMedRpt_062215.pdf" for Claim 06-358907 for IW Vanessa Ives **5**

Did You Know?

In a recent review of 312 independent medical exams for Ohio Industrial Commission PTD Hearings during the 2nd Quarter 2014, there were 248 injured workers with one or more spine allowed conditions that had neuromusculoskeletal evaluations by IC physicians. Workers with allowed spine conditions averaged 1¹/₃ spine region (cervical, thoracic or lumbar) injuries per person. When specialists evaluated injured worker spine impairment for PTD examinations, IC examiners used the **DRE method** in **85%** of the cases; the **ROM method** in **14%** of the cases. In rare cases, both methods were used in the same individual when two or three spine regions were allowed in the claim. The percentage of spine claims using specific Diagnostic Related Estimate Categories were: DRE II (24%), DRE IV (20%), DRE I (19%), DRE III (13%) and DRE V (10%).

R. Stanko MD, MS

CASE PRESENTATION

Ohio Industrial Commission - Specialist Report

CLAIMANT

Annie Labrador

ALLOWED CONDITIONS

SPRAIN NECK; SPRAIN LUMBAR REGION; HERNIATED NUCLEUS PULPOSUS L4-L5; SUBSTANTIAL AGGRAVATION OF PRE-EXISTING CERVICAL SPONDYLOSIS; SUBSTANTIAL AGGRAVATION OF PRE-EXISTING FORAMINAL STENOSIS C4-T1; RADICULOPATHY BILATERAL C5-C6; RADICULOPATHY LEFT L5.

HISTORY

The claimant was injured at work in 2010 when she fell backwards off a ladder. She states her neck surgery helped her symptoms somewhat, but she reports the plate in her neck is irritating and reports constant neck pain. She had no surgery to her lumbar spine. At home, she states she sits in a heated, vibrating chair which helps her back pain. She reports numbness and weakness in her hands bilaterally. She reports pain radiating down her left lower extremity and bilateral foot numbness. She states her standing tolerance is 5 minutes and her walking tolerance is 500 feet. She indicates occasional use of a cane for ambulation. She states she can drive a car for short distances, but usually her spouse does the driving. She states she does not go grocery store shopping.

Medical records indicate the claimant has had previous procedures: 02/20/2013, Anterior cervical microdiscectomy, partial corpectomy, decompression of central spinal canal and lateral foraminotomies of nerve roots C4-5, C5-6 and C6-7; with 50% resection of vertebral body and partial corpectomy C5 and C6 with intervertebral spacer; Cornerstone Cages C4-5, C5-6 and C6-7; with anterior cervical spinal instrumentation.

Prior to her cervical fusion surgery, Ms. Labrador had an MRI of the cervical and lumbar spine on 3/15/11 which showed a left L1-2 disc protrusion and a right L4-5 disc protrusion, multilevel cervical foraminal disease, severe left C4-5 foraminal narrowing, severe C5-6 bilateral foraminal narrowing, and severe right C7-T1 foraminal narrowing. An EMG on 9/3/11 showed mild fibrillation potentials at the C5-6 level and left L5-S1 levels. X-rays done on 12/26/10 reported degenerative lipping of the anterior and lateral borders of the cervical and lumbar vertebral bodies, and minimal facet arthritis of the lumbar spine.

X-rays taken by Dr. Vizsla on 10/10/12 show cervical osteophytes at C4-5, C5-6, C6-7; and foraminal encroachment at C4-5, C5-6, C6-7. An MRI of the cervical spine on 10/11/12 reported multilevel degenerative changes (unchanged from 2011) involving the vertebral body discs and facet joints. A neurology consult by Dr. Corgi on 11/14/12 reported normal exam findings in the upper and lower extremities. X-rays taken on 12/31/12 showed significant spondylitic protrusions on the right C5-6 and right C7-T1 levels; stenosis and spurring the left at C4-5, C5-6, and C6-7. A lumbar spine MRI done on 7/5/13 reported a L4-5 protrusion, moderate to severe stenosis L3-4 and a shallow L1-2 disc protrusion. An FCE exam on 12/17/13 opined that the claimant could perform work in the light work functional categories.

MEDICAL HISTORY REVIEW

Medications: Excedrin prn; Vicodin 5mg prn. (Has only taken two Vicodin in the last two months).

Past Medical History: Positive for diabetes, but under control. Denies current thyroid problems, ulcers, kidney problems, liver problems, hypertension, or anemia.

Review of systems: Reports no weight loss, chest pain, difficult breathing. Bowel and bladder function is normal. She reports some depression.

Social History: Does not smoke.

Family History: No diabetic family hx.

Allergies/Reactions: None.

PHYSICAL EXAM

The claimant is alert and in no acute distress. Respiration: regular. Radial and tibial pulses are intact bilaterally, 75/min. The skin shows normal color and temperature in the upper and lower extremities bilaterally. The claimant is 65 inches tall and weighs 163 pounds.

There is 5/5 strength for finger abduction, grip, wrist flexion, wrist extension, elbow flexion, elbow extension, shoulder abduction, shoulder external rotation and shoulder internal rotation bilaterally. There are absent DTRs for the biceps/triceps; trace brachioradialis bilaterally. Hoffman reflexes are negative bilaterally; no upper extremity spasticity noted. Sensation to light touch is intact in the upper arm and radial forearm bilaterally, but she reports decreased sensation over the left medial forearm and left hand. Mid-arm circumference measures 32 cm on the right and 31 cm on the left. A cervical compression test is negative. There is no scapular winging bilaterally. A Tinel test is negative bilaterally. There is a 4 cm well healed surgical scar noted over the right anterior neck. Neck range of motion shows 5° flexion, 5° extension, 15° right lateral flexion, 10° left lateral flexion, 20° right rotation and 15° left rotation. There is no tenderness reported with palpation of the cervical paraspinals bilaterally.

There is 4/5 strength for toe extension, foot dorsiflexion, knee extension, knee flexion and hip flexion bilaterally associated with pain inhibition from low back pain. DTR testing shows trace reflexes for the knees, hamstrings bilaterally. There is a 1+ right ankle DTR and an absent left ankle DTR. She reports that sensation to light touch is decreased throughout the left lower extremity. With SLR testing (sit), she reports increased back pain on the right at 45°; on the left at 30°. Gait is independent with a shorter stance phase on the left; she does use a cane for support. There is no spasticity noted in the lower extremities. Babinski testing is negative bilaterally. Leg circumference measures 34 cm. bilaterally (measured 10 cm below the tibial tuberosity). Sit-to-stand transfers are independent.

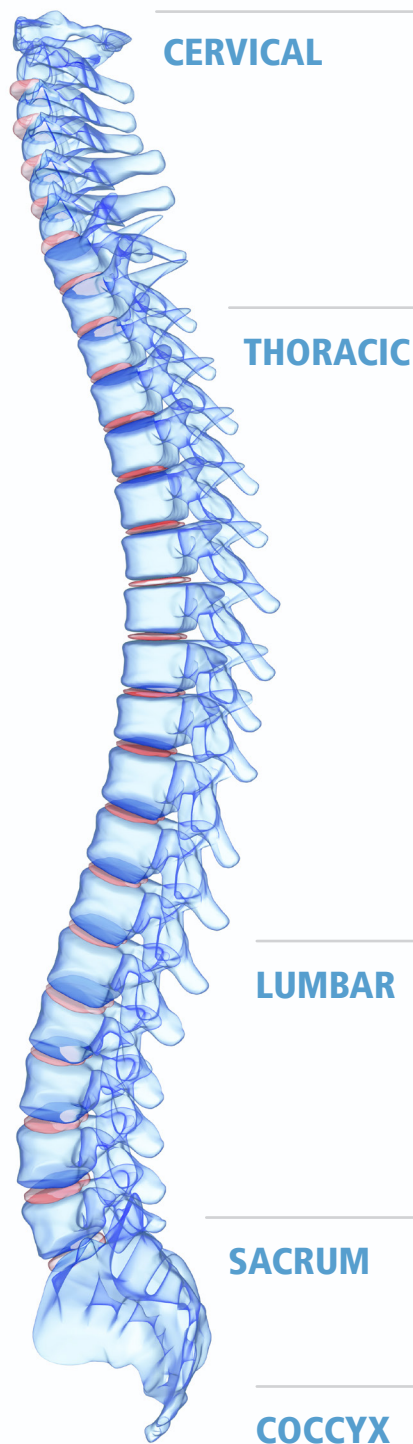
Back range of motion using an inclinometer shows 5° true lumbar flexion, 0° extension, 10° right lateral flexion and 10° left lateral flexion. No scoliosis is noted. There is no tenderness reported with palpation of the hips or sacroiliac joints bilaterally. She reports tenderness with palpation of the left gluteal muscles, none over the right. Tenderness is reported with palpation of lumbar paraspinals bilaterally. Hip range of motion shows 80° flexion, 5° external rotation and 5° internal rotation bilaterally. There are no scars are noted over the lumbar region.

DISCUSSION

SPRAIN LUMBAR REGION; HERNIATED NUCLEUS PULPOSUS L4-L5; RADICULOPATHY LEFT L5:

What is the most appropriate spine impairment evaluation method to use in the calculation of lumbosacral spine impairment?

What Tables / Figures in the *AMA Guides, 5th Edition* do you use to calculate impairment?



SPRAIN NECK; SUBSTANTIAL AGGRAVATION OF PRE-EXISTING CERVICAL SPONDYLOSIS; SUBSTANTIAL AGGRAVATION OF PRE-EXISTING FORAMINAL STENOSIS C4-T1; RADICULOPATHY BILATERAL C5-C6:

What is the most appropriate spine impairment evaluation method to use in the calculation of cervical spine impairment?

What Tables / Figures in the *AMA Guides, 5th Edition* do you use to calculate impairment?

How do you combine impairments of the cervical and lumbosacral spine regions?

PHYSICAL STRENGTH RATING:

What allowed condition impairments on physical exam affect strength?

What allowed condition impairments on physical exam affect ADL activities?

With respect to allowed conditions, what is your PSR strength and work capacity limitations? Why?

PROVIDE OPINIONS ON THE FOLLOWING ISSUES:

1. Has the Injured Worker reached maximum medical improvement with regard to each specified allowed condition? Briefly describe the rationale for your opinion. If "yes," then please continue to items #2 and #3.
2. Based on the *AMA Guides, 5th Edition*, and with reference to the Industrial Commission Medical Examination Manual, provide the estimated percentage of whole person impairment arising from each allowed condition. Please list each condition and whole person impairment separately, and then provide a combined whole person impairment. If there is no impairment for an allowed condition, indicate zero (0) percent.
3. Complete the enclosed Physical Strength Rating. In your narrative report, provide a discussion setting forth physical limitations resulting from the allowed conditions.

MediScene's Continuing Medical Education

All specialists doing physical or psychological evaluations for Industrial Commission PTD exams will undergo reappointment every five years. As part of this process, providers need to document eight hours of continuing medical education pertaining to specialty impairment evaluation. To assist in this endeavor, MediScenes will provide IME case presentations. Analyze the case, provide discussion, supporting rationale for your opinions, impairment ratings, and the physical strength or GAF ratings. Submit your report to IC Medical Services for 1 hour (Category 2) CME credit toward your IC education requirement. Submissions can be sent to wanda.mullins@ic.ohio.gov or sara.castle@ic.ohio.gov or faxed to (614)466-1051. An answer guide and CME certificate will be provided upon completion of your submission.

